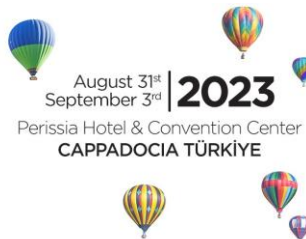

www.evrs2023.org

20th EVRS Meeting

“Combined Retinal Surgeries & Advances in Medical Retina”



ACCEPTED VIDEO PRESENTATIONS

The video prepared and submitted according to the announced guideline on will be displayed on video kiosks during the whole meeting. Please visit Abstracts page for guideline.

[Abstract:0097]

Surprise: Not Just the Vitreous Hemorrhage!

Mustafa Dogan, Mehmet Cem Sabaner
Afyonkarahisar Health Sciences University, Faculty of Medicine, Department of Ophthalmology,
Turkey

[Abstract:0123]

Dialysis of The 300 Degree Zonule In A Vitrectomized Eye

Yasin Sakir Goker
Goker Eye and Retina Center, Ankara, Turkey

[Abstract:0124]

25 G Sutureless Pars Plana Vitrectomy and ILM Peeling Without Laser Treatment for Optic Disc Pit Maculopathy

Yasin Sakir Goker
Goker Eye and Retina Center, Ankara, Turkey

[Abstract:0125]

Three Hand Method In Yamane Scleral Fixation In Patients With Aphakia

Yasin Sakir Goker
Goker Eye and Retina Center, Ankara, Turkey

[Abstract:0133]

The Dancing Delight

Manisha Agarwal
DR SHROFF'S CHARITY EYE HOSPITAL

[Abstract:0142]

Zero Cost Sclerotomy-anchored self-retaining Vitrectomy Contact Lens Holder for MIVS

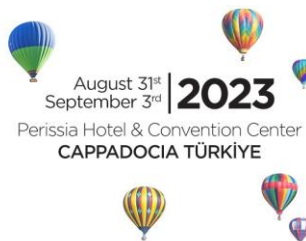Sangeet Mittal¹, Nishikant Borse²
¹Thind Eye Hospital, Jalandhar, India
²Insight Eye Clinic, Mumbai, India



20th EVRS Meeting

“Combined Retinal Surgeries & Advances in Medical Retina”

www.evrs2023.org



[Abstract:0149]

**What will you do in a different type of posteriorly dislocated IOL that you did not see before?
Rescue or Exchange**

Utku Limon

University of Health Sciences Umraniye Training and Research Hospital Eye Clinic Istanbul/Turkey

[Abstract:0154]

The Hidden Ghost ! Techniques of PVD Induction

Manisha Agarwal

[Abstract:0156]

Sewing the Cleft

Manisha Agarwal

Dr Shroff's Charity Eye Hospital

[Abstract:0166]

Management of a large metal intraocular foreign body

Meriem Abdellaoui, Hassan Moutei, Ahmed Bennis, Idriss Andaloussi Benatiya

University Hospital Hassan II, Ophthalmology department, Faculty Of Medicine Of Pharmacy And Dental Medicine, Fez Morocco

[Abstract:0167]

How aggressive should we be in the treatment of post-injection endophthalmitis with pars plana vitrectomy?

Utku Limon

University of Health Sciences Umraniye Training and Research Hospital Eye Clinic Istanbul/Turkey

[Abstract:0169]

Novel Technique to Manage Silicone Band Intrusion

Hussain Ahmad Khagan

PGMI,AMC,LGH,Lahore

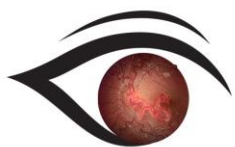
[Abstract:0180]

Primary Subretinal Hydatid Cyst

Huseyin Baran Ozdemir¹, Sengul Ozdek¹, Kaan Ozkan¹, Nalan Akyurek²

¹Department of Ophthalmology, Gazi University Faculty of Medicine, Ankara, Türkiye

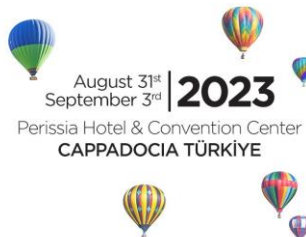²Department of Pathology, Gazi University Faculty of Medicine, Ankara, Türkiye



www.evrs2023.org

20th EVRS Meeting

“Combined Retinal Surgeries & Advances in Medical Retina”



[Abstract:0181]

Retinal Icicles

Manisha Agarwal

Dr Shroff'S CHARITY EYE HOSPITAL

[Abstract:0182]

Spinning the web

Manisha Agarwal

Dr Shroff's Charity Eye Hospital

[Abstract:0183]

Double Trouble

Manisha Agarwal

dR SHROFF'S CHARITY EYE HOSPITAL

[Abstract:0184]

Internal Drainage of the Choroid

Manisha Agarwal

DR SHROFF'S CHARITY EYE HOSPITAL

[Abstract:0218]

Diabetic total tractional retinal detachment

Yurdacan Demir¹, Melih Kurt²

¹Ozel Hayat Hastanesi, Bursa, Turkey

²Göz Nurunu Koruma Vakfı, Bursa, Turkey

[Abstract:0224]

Pvr after diabetic vitrectomy

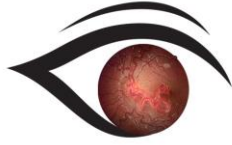
Yurdacan Demir¹, Melih Kurt²

¹Ozel Hayat Hastanesi, Bursa, Turkey

²Göz Nurunu Koruma Vakfı, Bursa, Turkey

[Abstract:0228]

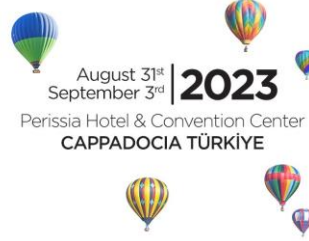Severe Mixed PFV: See The Light At The End Of The Funnel



www.evrs2023.org

20th EVRS Meeting

“Combined Retinal Surgeries & Advances in Medical Retina”



Ece Özdemir Zeydanlı¹, Şengül Özdek²

¹Ankara Retina Clinic, Ankara, Turkey

²Ophthalmology Department, Gazi University School of Medicine, Ankara, Turkey

[Abstract:0240]

Pars plana vitrectomy for fungal endogenous endophthalmitis in a patient receiving chemotherapy after operation for malign pancreas neoplasm

Dilek Güven

Acıbadem Maslak Hospital, İstanbul, Türkiye

[Abstract:0249]

Congenital cataract vs PFV

Omer Othman Abdullah

Ibinsina Modern Eye and Retina Center

[Abstract:0250]

Every case deserves a chance, a chronic suprachoroidal hemorrhage from no light perception to counting finger of one meter

Omer Othman Abdullah

Ibinsina Modern Eye and Retina Center

[Abstract:0259]

Perplexing case of initially presumed dropped nucleus 15 years after perforating trauma

Assem Mejaddam

Uppsala University Hospital

[Abstract:0280]

Tackling an evasive sub-foveal Cyst

Jayanto Shekhar Guha

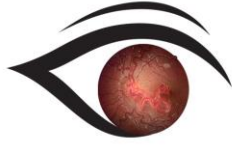
SRF Eye Hospital, New Delhi, India

[Abstract:0295]

10 years after Blunt Trauma... Dehydrated Amniotic Membrane Graft for the Rescue of a 1300 microns Macular Hole

Yassine Malek, Shamil Louaya

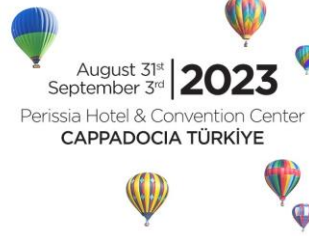Ophthalmology Department Agadir Military Hospital, Souss Massa University Hospital, Ibn Zhor University, Agadir, Morocco



www.evrs2023.org

20th EVRS Meeting

“Combined Retinal Surgeries & Advances in Medical Retina”



[Abstract:0334]

Hidden Metallic Foreign Body At Ora Serrata Behind Dense Vitreous

Mahmut Oğuz Uluso

Ophthalmology Department, Bursa Yüksek İhtisas Research Hospital, Bursa, Turkey

[Abstract:0341]

Posterior Vitreous Detachment in Old pediatric retinal detachment PFC assisted (mytricks)

Ahmed Mamdouh El Shafei

Research institute of ophthalmology (R.I.O) EGYPT

[Abstract:0352]

TRD Different strategies..!

Sara Ahmed Tawfik

Al-Ferdaws Eye Hospital, Egypt

[Abstract:0358]

Reper artificial iris and intraocular lens complex: a novel approach to traumatic aniridia

Gil Calvão Santos, Keissy Sousa, Petra Gouveia
Hospital de Braga

[Abstract:0363]

The use of Carlevalle IOL as a new simple idea

Keissy Sousa, Nuno Gomes, Gil Calvão Santos
Hospital de Braga

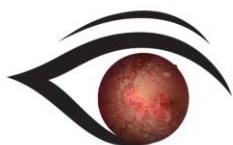
[Abstract:0367]

Scleral Fixation with Four Flanged Double Needle Technique

Gamze Dereli Can, Busra Yorulmaz

Department of Ophthalmology, Bursa City Hospital, Bursa, Turkiye

[Abstract:0384]



www.evrs2023.org

20th EVRS Meeting

“Combined Retinal Surgeries & Advances in Medical Retina”



Surgical treatment of globe ruptures

Paolo Chelini

Hospital of Lucca -Italy

[Abstract:0397]

Case of an intraocular foreign body removal with combined phacoemulsification+pars plana vitrectomy

Mehmet Erol Can, Eda Nur Gönültaş Özkan

Department of Ophthalmology, Bursa City Hospital, Bursa, Türkiye

[Abstract:0402]

Utilization of Intraoperative Optical Coherence Tomography in the Diagnosis of a Choroidal Tumor

Cem Kesim, Umit Yasar Guleser, Murat Hasanreisoglu

Department of Ophthalmology, Koç University School of Medicine

[Abstract:0405]

Bimanual Surgery for PDR and Table-top TRD - Its time for the ARROW

Sangeet Mittal

Thind Eye Hospital, Jalandhar

[Abstract:0415]

Last hope: into the darkness and beyond

Ahmed Mansour

Ophthalmology department, Ain Shams University, Cairo, Egypt

[Abstract:0416]

Stage 5 rop: 4 hands technique taming the monster

Ahmed Mansour

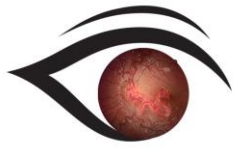
Ophthalmology, Ain Shams University, Cairo, Egypt

[Abstract:0417]

Fungal endophthalmitis.... the great mimicker

Ahmed Mansour

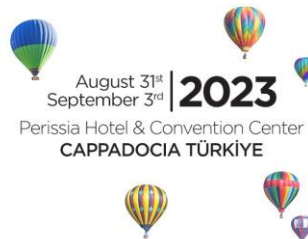Ophthalmology, Ain Shams University, Cairo, Egypt



www.evrs2023.org

20th EVRS Meeting

"Combined Retinal Surgeries & Advances in Medical Retina"



[Abstract:0418]

Buphthalmous... big eye think bigger

Ahmed Mansour

Ophthalmology department, Ain Shams University, Cairo, Egypt

[Abstract:0420]

Behcet Uveitis: Boggie under the bed

Ahmed Mansour

Ophthalmology department, Ain Shams University, Cairo, Egypt

[Abstract:0421]

Submacular Hge: From A-Z

Ahmed Mansour

Ophthalmology department, Ain Shams University, Cairo, Egypt

[Abstract:0422]

Chandelier Assisted Phaco: Same Technique different indications

Ahmed Mansour

Ophthalmology, Ain Shams University, Cairo, Egypt

[Abstract:0424]

Sub ILM hge: Unusual LASER Pen complication

Ahmed Mansour

ophthalmology department, Ain Shams University, Cairo, Egypt

[Abstract:0426]

A New Method for Removal of Subfoveal Perfluorocarbon Liquid (Bubble): Internal Limiting Membrane Peeling and Direct Aspiration

Mehmet Citirik, Mehmet Yasin Teke

University of Health Sciences, Ankara Etlik City Hospital

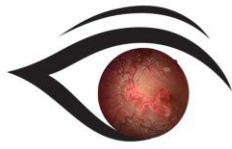
[Abstract:0435]

Large sized melanoma with extra ocular extension: Is there a way to conserve??

Ihab Saad Othman¹, Ihab Saad Othman²

¹Faculty of Medicine, Cairo University, Cairo, Egypt

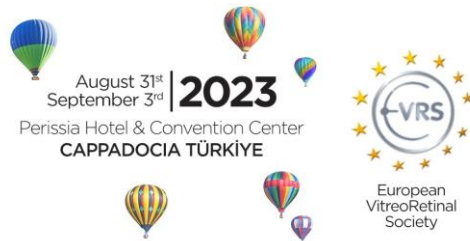²EyeWorld Hospital, Giza, Egypt



www.evrs2023.org

20th EVRS Meeting

“Combined Retinal Surgeries & Advances in Medical Retina”



[Abstract:0453]

The Mystery of the Missing Retinal Hole

Nishikant Jaywant Borse

Insight Eye Clinic, Mumbai, India

[Abstract:0462]

Use of RGP lens as Temporary Keratoprosthesis in Open-Sky Technique for Heterotopic Keratoplasty

Allurie Pulanco Ume¹, Richmond Ramirez Siazon¹, Maria Fideliz Dalisay De La Paz²

¹Department of Ophthalmology, Ilocos Training Regional and Medical Center, San Fernando City, La Union, Philippines

²Barraquer Ophthalmology Center, Barcelona, Spain

[Abstract:0478]

Nuances in management of Pediatric retinal detachments- A tale of 2 cases

Neeraj Sanduja, Charu Malik, Arnoev Sanduja

Viaan Eye and Retina Centre Gurgaon India

[Abstract:0485]

Bilateral Terson Syndrome with Sub-ILM Hemorrhage and Rare Finding of Hemorrhage Liquefaction and Taut ILM: A Case Report

Sadık Altan Ozal, Ece Ozal, Serhat Ermis, Murat Karapapak, Yusuf Cem Yılmaz, Serife Ciloglu Hayat, Hakan Baybora

Department of Ophthalmology, Basaksehir Cam and Sakura City Hospital, Istanbul, Türkiye

[Abstract:0488]

When the retina falls apart: Retinal detachment in Acute Retinal Necrosis

Katarzyna Chwiejczak

Sheffield Teaching Hospitals NHS Foundation Trust, University of Sydney

[Abstract:0490]

“The Abyss & What Lies Beneath!” – challenges in surgical management of Optic Disc Pit Maculopathy

Saurabh Luthra¹, Shrutanjay M Das¹, Shweta Parakh¹, Vaibhav Bhatt¹, Abhijaat Chaturvedi¹, Neeraj Sanduja², Nishikant Borse³, Sangeet Mittal⁴

¹Department of Vitreoretina and Uvea, Drishti Eye Institute, Dehradun, India

²Department of Retina, Viaan Eye Centre, Gurgaon, India

³Department of Retina, Insight Eye Clinic, Mumbai, India

⁴Department of Retina, Thind Eye Hospital, Jalandhar, India



www.evrs2023.org

20th EVRS Meeting

“Combined Retinal Surgeries & Advances in Medical Retina”



[Abstract:0497]

Treatment of a Giant Macular Tear with Amniotic Membrane in a Case of Shaken-Baby Syndrome with RRD Associated with Dialysis and Giant Retinal Break

Huseyin Baran Ozdemir, Sengul Ozdek, Merve Nur Yilmaz
Department of Ophthalmology, Gazi University Faculty of Medicine, Ankara, Türkiye

[Abstract:0504]

Combined internal limiting membrane and polypropylene monofilament plug for recurrent optic pit maculopathy

Berkant Kaderli
Nev Health Group FSM Hospital

[Abstract:0510]

Techniques of lens implantation in the absence of capsular support

Maria Cristina Soare, Karina Spiess, Mostafa A Elgohary
Kingston Hospital NHS Foundation Trust

[Abstract:0515]

Macular dragging relief

Filipe Henriques, Luis Bernardes, Telma Machado, Rosa Pinheiro
Centro Hospitalar e Universitario de Coimbra

[Abstract:0519]

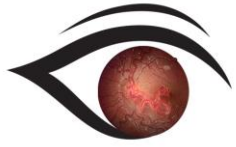
Chandelier-Assisted Scleral Buckling with Illuminated Endolaser Retinopexy-A Different Option

Nur Acar Gocgil
NUR ACAR GOCGİL, Prof, FEBO, Neoretina Eye Clinic, Istanbul, Turkey

[Abstract:0525]

Temporary PFCL tamponade for for endoresection of choroidal melanoma

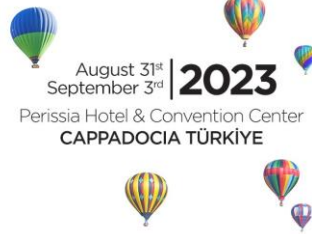Hany Hamza
Kasr Al Any School of Medicine Cairo University Egypt



www.evrs2023.org

20th EVRS Meeting

"Combined Retinal Surgeries & Advances in Medical Retina"



[Abstract:0558]

Autologous retina transplant for a huge traumatic macular hole

Jayanto Shekhar Guha

SRF Eye Hospital, New Delhi, India